

## Case report

# SUBACUTE ADRENAL HEMORRHAGE BY BLUNT ABDOMINAL CONTUSION DURING SNOWBOARDING

## SUBACUTE ADRENAL HEMORRHAGE BY BLUNT ABDOMINAL CONTUSION

Hiroshi USHIDA<sup>1)</sup>, Kazuyoshi JOHNIN<sup>1)</sup>, Shuichi KOIZUMI<sup>2)</sup>,  
Takashi KADOWAKI<sup>3)</sup>, Tomoya MASADA<sup>2)</sup>  
AND Yusaku OKADA<sup>1)</sup>

1) The Department of Urology

2) The Department of Urology and Radiology, Uji Tokushukai Hospital

3) The Department of Health Science

**Abstract** The adrenal glands lies deep in the abdomen, seemingly protected from blunt contusion. We report a case of a young female presenting left adrenal hemorrhage due to blunt abdominal contusion caused by a collision during snowboarding, which was successfully treated with embolization.

**Keyword** subacute adrenal hemorrhage, blunt abdominal contusion, embolization

### INTRODUCTION

As snowboarding is becoming popular as a winter sport among young people, the number of accidents has been increasing rapidly<sup>1)-3)</sup>. Extremities are the most frequently affected by such accidents, but visceral injuries are rare<sup>1)-3)</sup>. We report a case of a young female presenting left adrenal hemorrhage by blunt abdominal contusion caused by a collision during snowboarding, which was successfully treated with embolization.

### CASE REPORT

A 22-year-old woman visited our hospital with a complaint of left back pain presenting for two weeks. Vital signs were normal with blood pressure

106/72mmHg and pulse rate 92/min. However, hematological examination revealed severe anemia, with hemoglobin 5.7g/dl and hematocrit 17.8%. Abdominal ultrasonography (US) revealed a heterogeneous retroperitoneal mass of 10cm in diameter, between the left kidney and the spleen. Computed tomography (CT) showed a left adrenal mass (8 × 7 × 10cm in diameter), which was heterogeneous on contrast enhancement, and an injury in the lower pole of spleen (Fig. 1-A). CT also showed fluid collection in the pelvic cavity. We suspected rupture of the left adrenal tumor at first. However, by detailed history talking, we noticed that she had a history of abdominal contusion by collision with some other snowboard player two weeks before.

Based on this clinical history, we made the diagnosis of left adrenal hematoma induced by abdominal contusion. Emergency abdominal angiography was performed to find the bleeding sites. Angiography showed the peripheral branch bleeding of left superior and inferior adrenal arteries (Fig. 2-A, B). To stop bleeding, embolization using gelform was performed. The splenic artery was compressed laterally by the retroperitoneal hematoma, although itself bleeding points were not clarified. Possibility of hemorrhage due to rupture of the left adrenal tumor was completely ruled out by magnetic resonance imaging (MRI). During the long-term follow-up, CT performed 6 months later showed cystic mass with thick wall without tumor signs (Fig. 1-B), and 36 months later cystic mass disappeared.

## DISCUSSION

The adrenal glands lie in the perirenal space surrounded by fat and enclosed by the fascia of Gerota. The adrenal glands lie deep in the abdomen, seemingly protected from traumatic contusion. General causes of adrenal hemorrhage include fulminant septicaemia (Waterhouse-Friderichsen syndrome), birth trauma during delivery in new born babies, venography for adrenal gland, particularly resulting from infarction of adrenal adenoma, post-myocardial infarction especially in patients on thrombolytic and anticoagulation therapy, and rarely follow idiopathic adrenal vein thrombosis. On the other hand, traumatic hemorrhage of the adrenal gland is being identified with increasing frequency and may be present in up to 25% of severely traumatized patients<sup>4</sup>. They reported that the prevalence of adrenal bleeding among patients with blunt abdominal trauma undergoing CT scanning is 2%, among which 60% occur on the right side, 25% on the left and 15% are bilateral<sup>4</sup>. They are typically small, asymptomatic and resolve spontaneously. Post-traumatic adrenal pseudocyst has been reported to be observed. Two possible mechanisms of traumatic hemorrhage in the

right adrenal gland are (a) direct compression of the gland between the spine and the liver and (b) an acute rise in intraadrenal venous pressure due to compression of the inferior vena cava with adrenal hemorrhage as a secondary reaction<sup>5</sup>. The third possibility is that the hemorrhage may be secondary to decelerative forces, which cause shearing of small vessels that perforate the adrenal capsule<sup>5</sup>. In our case the cause of traumatic hemorrhage in the left adrenal gland was unidentified, but we assumed direct compression of the gland between the spleen and the spine when occurred the splenic injury. Management of adrenal hemorrhage has continued to be either surgical or conservative, but our case was successfully treated with embolization, thereby obviating surgical exploration of the abdomen. To our knowledge there are only few reports<sup>6-9</sup> on the treatment with embolization for unilateral adrenal hemorrhage. Our case suggests that angiography and embolization procedure is a viable alternative to surgical exploration in the management of unilateral traumatic adrenal injuries.

## REFERENCES

1. Abu-Laban RB. : Snowboarding injuries : an analysis and comparison with alpine skiing injuries. *CMAJ*, 145(9): 1097-1103, 1991.
2. Bladin C., McCrory P. : Snowboarding injuries. An overview. *Sports Med*, 19(5): 358-364, 1995.
3. Davidson TM., Laliotis AT. : Snowboarding injuries, a four-year study with comparison with alpine ski injuries. *West J Med*, 164(3): 231-237, 1996.
4. Burks D.W., Mirvis S.E., Shanmuganthan K. : Acute adrenal injury after blunt abdominal trauma : CT findings. *Am J Roentgenol*, 158(3): 503-507, 1992.
5. Murphy B.J., Casillas J., Yrizarry J.M. : Traumatic adrenal hemorrhage : Radiologic findings. *Radiology*, 169(3): 701-703, 1988.
6. Igwilo O.C., Sulkowski R.J., Shah M.R.,

Messink W.F., Kinnas N.C. : Embolization of traumatic adrenal hemorrhage. *J Trauma*, 47(6): 1153-1155, 1999.

7. Ikeda O., Urata J., Araki Y., Yoshimatsu S., Kume S., Torigoe Y., Yamashita Y. : Acute adrenal hemorrhage after blunt trauma. *Abdom Imaging*, 32(2): 248-252, 2007.
8. John W.K., Michael D.K., Victoria M.M., Donald S.H., Sue E.H. : N-Butyl Cyanoacrylate Embolization for Control of Acute Arterial Hemorrhage. *JVIR*, 15(2): 689-695, 2004.
9. Julei C., Irum B., John M., Lena M. : Adrenal artery rupture in pregnancy. *BJOG*, 111(2): 185-187, 2004.

### LEGEND FOR FIGURES

Fig. 1-A Contrast enhanced CT showed a left adrenal heterogeneous mass ( $8 \times 7 \times 10$  cm) and an injury in the lower pole of spleen.

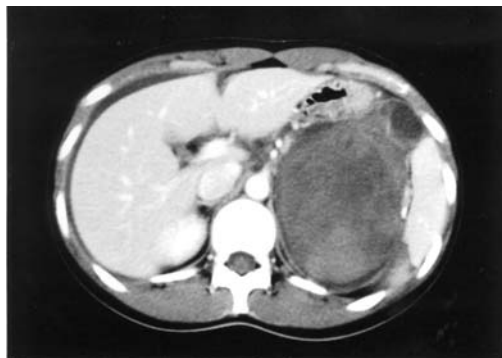
1-B Plain CT showed a cystic mass with a thick wall without a tumor sign 6 months later.

Fig. 2-A, B Angiography showed left superior and inferior adrenal arterial bleeding.

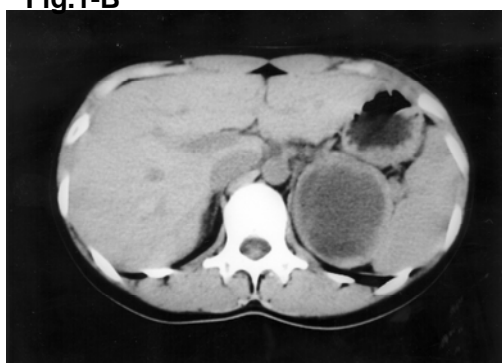
Arrow ① ; left inferior phrenic artery,  
Arrow ②; left superior adrenal artery

Arrow ③ ; left inferior adrenal artery,  
Arrow head ; extravasation

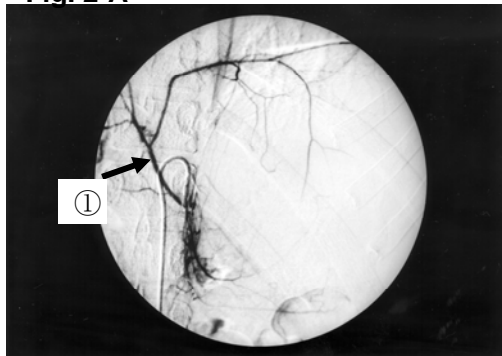
**Fig.1-A**



**Fig.1-B**



**Fig. 2-A**



**Fig. 2-B**

